

Idiopathic intracranial hypertension

Atypical presentation

Hussein A. Algahtani, MBChB, FRCP(C), Saleh S. Baeesa, MBChB, FRCS(C), Tahir H. Obeid, FRCP, FAAN, Ahmad R. Abuzinadah, MBBS.

ABSTRACT

Objectives: To describe the clinical features of 5 patients with rare atypical presentation of idiopathic intracranial hypertension (IIH), and propose the possible mechanism of this atypical presentation.

Methods: We carried out a retrospective study of 5 patients admitted at King Khalid National Guard Hospital, Jeddah, Kingdom of Saudi Arabia with IIH during the period from January 2001 to December 2005. All were females with their age ranges from 24 to 40 years. The clinical presentations, and the laboratory and imaging studies were analyzed. The opening pressures of the lumbar puncture tests were documented.

Results: All patients were presented with headache. One had typical pain of trigeminal neuralgia, and one with neck pain and radiculopathy. Facial diplegia was present in one patient, and 2 patients had bilateral 6th cranial neuropathy. Papilledema was present in all patients except in one patient. Imaging study was normal in all patients, and they had a very high opening pressure during lumbar puncture, except in one patient. All patients achieved full recovery with medical therapy in 6 to 12 weeks with no relapse during the mean follow up of 2 years.

Conclusions: Atypical findings in IIH are rare and require a high index of suspicion for early diagnosis.

Saudi Med J 2007; Vol. 28 (5): 762-765

From the Division of Neurology (Algahtani, Obeid, Abuzinadah), King Khalid National Guard Hospital, Division of Neurological Surgery (Baeesa), King Abdul-Aziz University Hospital, Jeddah, Saudi Arabia.

Received 28th August 2006. Accepted 16th December 2006.

Address correspondence and reprint request to: Dr. Hussein A. Algahtani, Consultant Neurologist, Neurology Division, Department of Medicine, King Khalid National Guard Hospital, PO Box 12723, Jeddah 21483, Kingdom of Saudi Arabia. Tel. +966 (2) 6240000 ext. 1298 / 2070. Fax. +966 (2) 6240000 ext. 2765. E-mail: halgahtani@hotmail.com

The syndrome of increased intracranial pressure without hydrocephalus or mass lesion and in the presence of normal cerebrospinal fluid (CSF) composition was previously referred to as pseudotumor cerebri. Commonly, it is called idiopathic intracranial hypertension (IIH) and the diagnosis is usually made by exclusion.¹ It typically presents with headache, blurred vision and papilledema, and the diagnosis can be established using modified Dandy criteria as the following:² 1. Symptoms, if present, reflect only those of increased intracranial pressure or papilledema. 2. Signs are attributable only to increased intracranial pressure or papilledema. 3. Documented elevated intracranial pressure during lumbar puncture measured in lateral decubitus positions. 4. Cerebrospinal fluid composition is normal. 5. There is no ventriculomegaly, mass, structural, or vascular lesion on neuroimaging studies. 6. If no other cause of intracranial hypertension is identified, the syndrome is termed as idiopathic intracranial hypertension.

Rarely, it may have atypical features, which render the diagnosis difficult. The authors describe atypical presentation of IIH in 5 patients. The possible mechanisms were discussed and the literature was reviewed.

Methods. Retrospective review of 5 patients treated in the Neurology Division at King Khalid National Guard Hospital, Jeddah, Kingdom of Saudi Arabia during January 2001 to December 2005. The clinical presentation and other data were summarized in **Table 1**. All patients were diagnosed as IIH based on clinical presentations and absence of hematological and endocrine causes. Magnetic resonance imaging (MRI), venography (MRV) and angiography (MRA) scans were carried out in all patients with no evidence of sinus thrombosis or intracranial space occupying lesions. The CSF examination including opening pressure measurement was carried out in all patients. Detailed ophthalmologic

examination was routinely carried out in all patients before treatment and during follow up. They were followed for 5 years (mean, 2 years) and the outcome was defined on the basis of symptoms and fundoscopic findings. All patients were Saudi females with age ranged from 24-40 years (mean, 30 years). The patient had symptoms for 4-12 weeks (average, 7.2 weeks) before establishing the diagnosis. Patients were presented with moderate to severe headache, but one of the patient (case number 1, **Figure 1**) had a classic trigeminal neuralgia pain that was sharp, electrical-like character, lasting 2-3 seconds and involving right lower half of the face. We noticed that the trigger point was above or lateral to the right angle of the mouth and it triggered by chewing, touching or washing the face and speaking. Nausea and occasional vomiting was reported in all patients. Neurological examination revealed papilledema in all except in one case (case number 5). Cranial neuropathy of the 6th nerve was reported in 3 patients, and one of them (case number 4) had associated bilateral 7th nerve palsy in which the nerve conduction study (NCS) and electromyography (EMG) were normal. One patient, known case of IIH treated successfully 2 years ago with medical therapy, presented with neck and bilateral shoulders and arms pain for 2 weeks (case number 2). Her motor examination showed markedly diminished power in proximal muscles of both upper limbs with

absent tendon reflexes, and the rest of neurological examination, including lower limb examination was normal. In this particular case, the result of the MRI scan of the cervical spine (as well as brain) was normal. On ophthalmologic examination, she had enlarged blind spot with bilateral papilledema and bilateral 6th nerve palsy, and the LP showed an opening pressure of 420 mm H₂O and normal CSF analysis. Her NCS was normal and EMG showed fibrillation potentials in the upper extremity and cervical paraspinal muscles. She progresses to develop extensive radiculopathy with weakness of lower limbs with disappearance of knee jerks. All patient had lumbar puncture with detailed documentations of the opening pressure, which was normal in one patient (case number 3), but was very high in 4 patients with a range of 380-450 mm H₂O (average, 412 mm H₂O). Cell counts, chemical, and cytological analysis as well as culture of the CSF were normal in all patients. All patients were obese with an average body mass index (BMI) of 24.

Results. The patients were followed up in the neurology clinic for 5 years (mean, 2 years). All of them received acetazolamide therapy for an average of 12 weeks with no complications reported. Repeated therapeutic lumbar puncture (LP) was required in 2 patients and no patients required permanent surgical

Table 1 - Summary of the five cases treated.

Case	Age (year)	Gender	Duration of symptoms	Clinical presentation	MRI/MRV	CSF opening pressure (mm H ₂ O)	Treatment	Outcome
1	36	F	8 weeks	Trigeminal neuralgia and papilledema	Normal	400	Acetazolamide	Full recovery
2	24	F	12 weeks	Headache, visual obscuration, weak upper and lower extremities, bilateral papilledema, 6th cranial nerve palsy	Normal	360	Acetazolamide steroid and IVIG	Full recovery
3	24	F	4 weeks	Headache, nausea, vomiting, photophobia, papilledema and left 6th cranial nerve palsy	Normal	Normal	Acetazolamide	Full recovery
4	26	F	4 weeks	Headache, diplopia, papilledema, bilateral 6th and 7th cranial nerve palsies	CT head Normal (MRI not done)	450	Acetazolamide	Full recovery
5	40	F	8 weeks	Headache, nausea, vomiting, visual obscuration, tinnitus, no papilledema	Normal	380	Acetazolamide	Full recovery

MRI - magnetic resonance imaging, MRV -venography, CSF - normal cerebrospinal fluid, IVIG - intravenous immunoglobulin therapy

intervention. All showed complete resolution of their headache including trigeminal neuralgia in case number one. Resolution of papilledemas were observed on regular ophthalmologic examination; 2 patients have residual decreased visual acuity and abnormal visual fields but they were no corrective glasses required. Patient number 2, who presented with an extensive radiculopathy, as a manifestation of IIH, was treated with intravenous pulse steroid therapy, intravenous immunoglobulin and acetazolamide therapy. She was fully recovered after 18 weeks, but unfortunately she declined NCS and EMG follow up study. Cranial neuropathies of the 6th and 7th nerves were completely resolved in patients 2, 3, and 4.

Discussion. Atypical presentation of IIH is a rare occurrence, and the exact mechanism is not well understood. There are some hypotheses from few cases published in the literature have been postulated and may explain such rare presentations. The association of IIH with trigeminal neuralgia was recently reported by Davenport et al³ in one patient. In our study, we reported the sixth case of such presentation wherein symptoms were resolved completely following LP and acetazolamide therapy. The close relationship between the reduction of CSF pressure and an improvement of the trigeminal neuralgia may indicate that it is caused by increased intracranial pressure. The mechanisms were postulated due to direct compression of the trigeminal nerve by cerebral tissue, traction of the nerve by caudal displacement of the brainstem, or vascular disturbance secondary to the first 2 insults.³ Radiculopathy is another rare presentation of IIH first reported by Bortoluzzi et al.⁴ The mechanical compression of the nerve roots due to elevated CSF pressure is the most likely etiologic mechanism. This theory was supported by Moosa et al⁵ who reported a similar patient who presented with IIH and radicular pain and areflexia. The MRI study in their case documented the enlargement of spinal subarachnoid spaces and distended roots pouches; such sign were not present in our patient. The IIH with normal opening pressure was present in one of our patient (case number 3) that was reported in the literature by Green et al⁶ who called it "normal pressure pseudotumor cerebri". The exact mechanism remains unknown; however, normal opening pressure in between the episodes of paroxysmal intracranial hypertension could explain this rare phenomenon.⁷ Facial diplegia has been the presentation of one of our patients (case number 4) and we considered it as one of the rare presentations of IIH. In children, there are reports of unilateral facial nerve involvement by Chutorian et al,⁸ which resolved spontaneously.⁸ They reported it as possible association of IIH and Bell's palsy. Kiwak and Levine⁹ described a

case of pseudotumor cerebri with facial diplegia, who showed complete resolution of signs and symptoms after adequate control of the increased intracranial pressure by lumboperitoneal shunting.⁹ Recently, Bakshi et al¹⁰ reported another case and proposed that facial nerve involvement may be explained by increased intracranial pressure in the posterior fossa displacing the nerve so that it is stretched through its entire length in the facial canal. Idiopathic intracranial hypertension without papilledema (IIHWOP) was presents in one of patients (case number 5) and approximately 73 cases were reported in the literature. This is also called papilledema negative idiopathic intracranial hypertension by Huff et al.¹¹ In the same year, Winner and Bello¹² reviewed the literature and proposed that the mechanism may be due to bilateral congenital optic nerve sheath defects, chronic pseudotumor cerebri with resolution of papilledema, or interstitial elevation of intracranial pressure below the threshold to produce papilledema. Although the risk of permanent visual loss may be lower in IIHWOP than IIH population as a whole; thus, those patients should receive careful baseline and follow-up evaluation by an ophthalmologist.¹¹ Wang et al¹³ reported one case control study in headache stating that the association of pulsatile tinnitus and obesity may suggest the possible diagnosis of IIHWOP in patients with chronic daily headache. In another study, Mathew et al¹⁴ recommended that patients with chronic daily headache with migraines features who is refractory to conventional therapy with prophylactic antimigraine therapy should have LP to exclude coexisting IIH. Our study shows that the result of the management of 5 young female patients with unusual presentation of IIH was excellent. Fortunately, all patients had complete

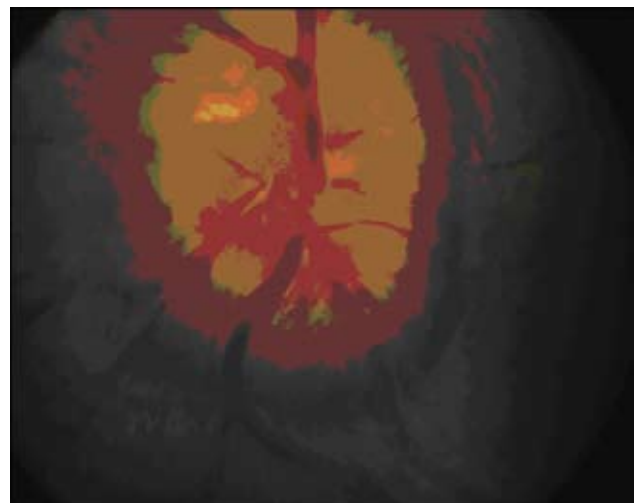


Figure 1 - Fundoscopic photography of case #1 demonstrating marked papilledema.

recovery after treatment despite of the 4 to 12 weeks delay in diagnosis. The majority of the reported cases with atypical presentation of IIH in the literature had good outcome. The fact that the study sample was small and had a short time follow up, comparison with the classic IIH is not possible.

Although IIH is not an uncommon disorder that can be easily diagnosed, it can present in atypical way that makes the diagnosis challenging. We emphasize and increase the awareness and attention of such rare presentation of IIH among physicians for earlier diagnosis and treatment to help prevent its complications.

References

1. Hanky J, Wardlaw M. Clinical Neurology. London (UK); Manson Publishing; 2002. p. 477.
2. Friedman DI. Pseudotumor Cerebri. *Neurol Clin* 2004; 22: 99-131.
3. Davenport RJ, Will RG, Galloway PJ. Isolated intracranial hypertension presenting with trigeminal neuropathy. *J Neurol Neurosurg Psychiatry* 1994; 57: 381.
4. Bortoluzzi M, Di Lauro L, Marini G. Benign intracranial hypertension with spinal and radicular pain. Case report. *J Neurosurg* 1982; 57: 833-836.
5. Moosa A, Joy MA, Kumar A. Extensive radiculopathy: another false localizing signs in intracranial hypertension. *J Neurol Neurosurg Psychiatry* 2004; 75: 1080-1082.
6. Green JP, Newman NJ, Stowe ZN, Nemeroff CB. "Normal pressure" pseudotumor cerebri. *J Neuroophthalmol* 1996; 16: 241-246.
7. Torbey MT, Geocadin RG, Razumovsky AY, Rigamonti D, Williams MA. Utility of CSF pressure monitoring to identify idiopathic intracranial hypertension without papilledema in patients with chronic daily headache. *Cephalalgia* 2004; 24: 495-502.
8. Chutorian AM, Gold AP, Braun CW. Benign intracranial hypertension and Bell's palsy. *N Engl J Med* 1977; 296: 1214-1215.
9. Kiwak KJ, Levine SE. Benign intracranial hypertension and facial diplegia. *Arch Neurol* 1984; 41: 787-788.
10. Bakshi SK, Oak JL, Chawla KP, Kulkarni SD, Apte N. Facial nerve involvement in pseudotumor cerebri. *J Postgrad Med* 1992; 38: 144-145.
11. Huff AL, Hupp SL, Rothrock JF. Chronic daily headache with migrainous features due to papilledema-negative idiopathic intracranial hypertension. *Cephalalgia* 1996; 16: 451-452.
12. Winner P, Bello L. Idiopathic intracranial hypertension in a young child without visual symptoms or signs. *Headache* 1996; 36: 574-576.
13. Wang SJ, Silberstein SD, Patterson S, Young WB. Idiopathic intracranial hypertension without papilledema: a case-control study in a headache center. *Neurology* 1998; 51: 245-249.
14. Mathew NT, Ravishankar K, Sanin LC. Coexistence of migraine and idiopathic intracranial hypertension without papilledema. *Neurology* 1994; 46: 1226-1230.

Related topics

Borhani-Haghighi A, Samangoie S, Ashjazadeh N, Nikseresht A, Shariat A, Yousefipour G, Safari A. Neurological manifestations of Behcet's disease. *Saudi Med J* 2006; 27: 1542-1546.

Koul RL, Chacko A, Leven HO. Dandy-Walker syndrome in association with neurofibromatosis in monozygotic twins. *Saudi Med J* 2000; 21: 390-392.

Al Khuwaitir TS, Wani BA, Dawood HA, Khan MA. Successful outcome after evacuation of intracranial hematoma following thrombolysis in acute myocardial infarction. *Saudi Med J* 2005; 26: 130-132.